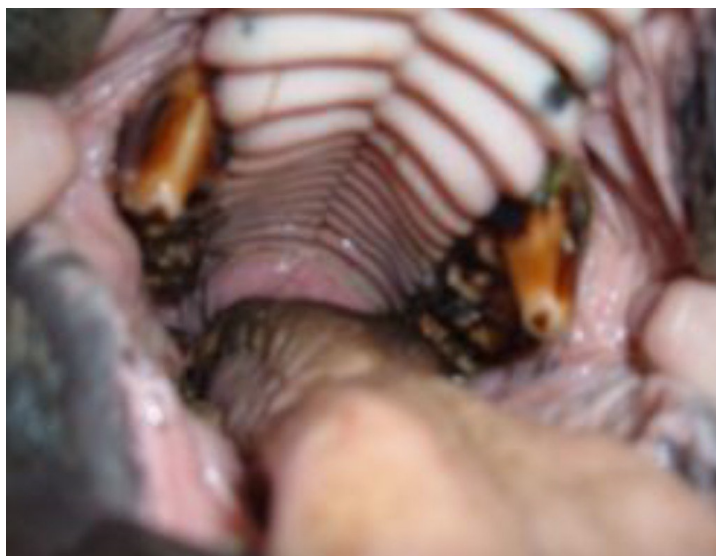

## Some dentistry problems needing attention

Huge tusks in the upper jaw which have been preventing this donkey from eating properly as they impact on the lower jaw long before the other teeth can make contact to chew.

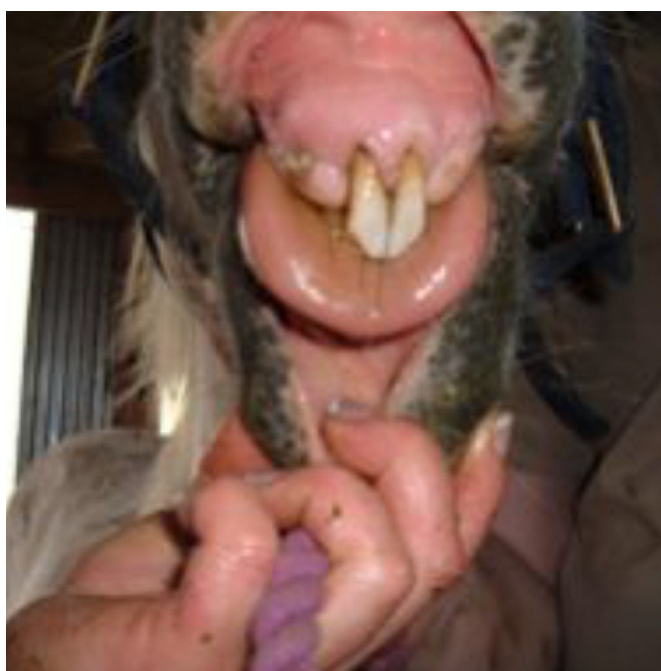
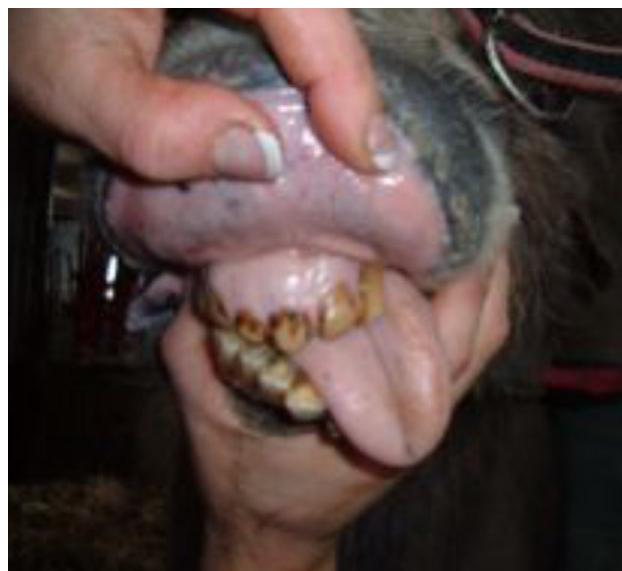These need to be reduced in size until they are at the same level as the other teeth, then the donkey will be able to chew his food properly again.



This donkey's jaw had been broken, probably by being kicked by a pony, but it had gone unnoticed.

The teeth are so out of alignment that her tongue falls out to one side along with most of the food she tries to chew.

The dentist can reshape the mouth to some extent to improve the "bite" and her ability to grind up the food with her back teeth (molars)



This elderly pony has only two front teeth left with which to nip the grass when he is grazing. By levelling off the surfaces of these teeth, he will be able to cut the grass more easily. He has a few mis-shapen back molars so he can be fed some "hard-feed" (concentrates) but this needs to be monitored carefully, as like most ponies, he is prone to laminitis